

A MYSTICAL CASE OF DERMOID CYST IN PAROTID GLAND: A CASE REPORT

Tanweer Hussain Bangash¹, Rubab Mumtaz², Lubna Arshad Azam Raja³, Abdullah Khan⁴

¹Oral and Maxillofacial Surgeon, Department of Oral and Maxillofacial Surgery, DHQ, Haripur, KPK, Pakistan. ²Oral and Maxillofacial Surgeon, RHC, Srikot, Haripur, KPK, Pakistan. ³Oral and Maxillofacial Resident, Armed Forces Institute of Dentistry (AFID), Rawalpindi, Pakistan. ⁴Resident Oral and Maxillofacial Surgery (OMFS) DHQ Hospital, Haripur, Pakistan

ABSTRACT

Dermoid cysts (DC) are benign tumors that rarely occur in the parotid gland and are composed of ectodermal and mesodermal cells. Fewer cases of dermoid cysts occurring in the parotid gland have been reported so far. We report here a case of a patient who presented with slow growing tumor on the right side of his face for the past 4 years. He underwent a superficial parotidectomy with intact facial nerve post operatively. Histopathological examination of the resected tumor specimen revealed a DC.

Keywords: Dermoid, Facial nerve, Parotid, Parotidectomy.

How to cite: Bangash TH, Mumtaz R, Raja LAA, et al. A mystical case of dermoid cyst in parotid gland: A case report. HMDJ. 2023; 03(02): 68-70.

INTRODUCTION

Dermoid cysts (DC) are rare, slow-growing benign tumors that can occur anywhere in the body¹. Less than 7% of these cysts involve head & neck region, with only 1.6% occurring in the oral cavity. They usually appear as a midline mass in the neck and rarely present in the lateral region. Very few cases of DC involving parotid gland have been reported till date^{1,2}. These cysts are either congenital that arise from a rest of embryonic epithelium or acquired as a result of traumatic implanted skin in the deeper layers².

Incidence of DC in parotid gland is rare. About 80% occur in the orbit, floor of the mouth (FOM) and nose, FOM being the second most common region in head & neck after the lateral eyebrow³. Greater than 50% of cases in head & neck are detected before 6 years of age with one-third presenting at birth^{1,2}.

Histologically, DC is composed of tissues arising from ectoderm and mesoderm. These cysts are lined by stratified squamous epithelium containing variable number of dermal appendages such as hair follicles, hair shafts, sebaceous

and sweat glands that are supported by a fibrous connective tissue wall^{2,3}.

Clinically these cysts are usually asymptomatic unless they grow large enough to result in cosmetic or functional defects². Malignant transformation of DC is extremely rare (5%), which has been previously determined in the head & neck, ovarian, intracranial and lumbar sites^{3,4}.

CAPSULE SUMMARY

- Dermoid Cyst, a rare occurring in the parotid gland, is reported here.
- Histopathology gave the clear diagnosis.
- Superficial Parotidectomy, ensuring the protection of facial nerve, was done.

In this case report, we present a rare case of DC arising in the parotid gland along with its management. Consent was taken and patient is unidentifiable in the pictures.

CASE REPORT

A 39-year-old male presented to our department with a gradually enlarging, painless swelling in his right parotid gland for the last 04 years. He was medically fit and had no history of trauma, smoking or surgery. On examination there was a firm, non-tender, non-fluctuant, non-pulsatile, 3.5x2.5cm swelling that was adherent to the overlying and underlying structures (Figure 1). Facial nerve was intact. Ultrasound-guided Fine Needle Aspiration Biopsy (FNAB) was done, that was inconclusive. No other radiographic investigations were done. After pre-anaesthesia work-up, a superficial parotidectomy, with modified Blair's incision, was carried out under general anaesthesia. The lesion was exposed. It had a well-defined, thin capsule. During dissection, this capsule got ruptured and dirty cheesy material started to pool in the surgical field. Branches of the Facial nerve were identified, monitored and secured (Figure 2). Encapsulated mass was

Correspondence to: Dr. Tanweer Hussain Bangash, Oral and Maxillofacial Surgeon, Department of Oral and Maxillofacial Surgery, DHQ, Haripur, KPK, Pakistan.

Email: tanweer_bangash@hotmail.com

Conflict of interest: None

Financial Disclosure: None

Received: 01-02-2024

Accepted: 01-02-2024

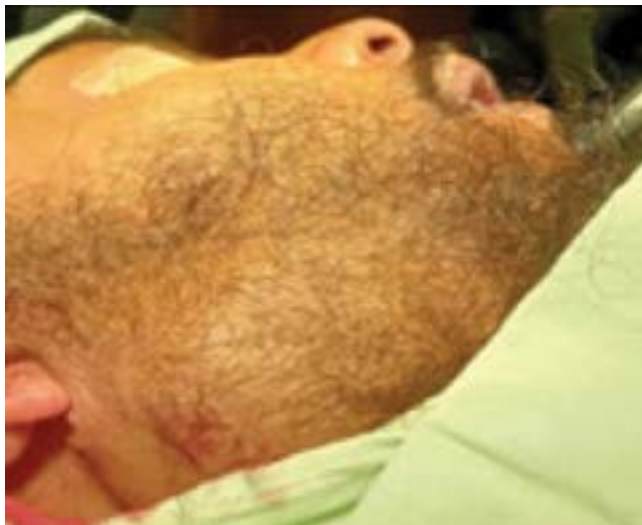

Figure 1: Swelling on the right side of the face.

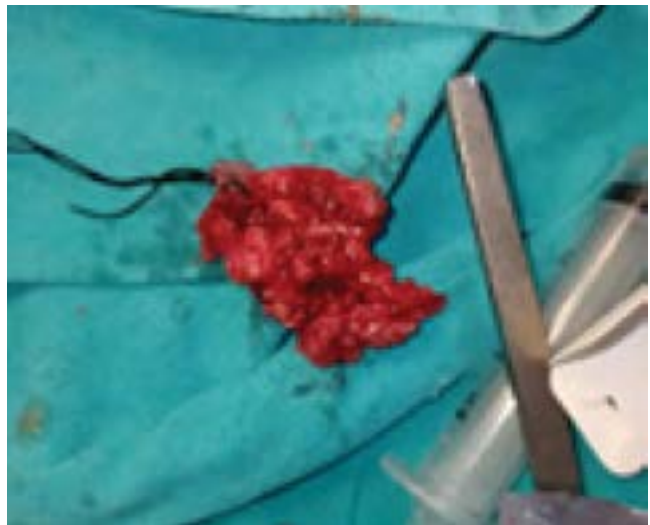


Figure 3: Excised Dermoid cyst.

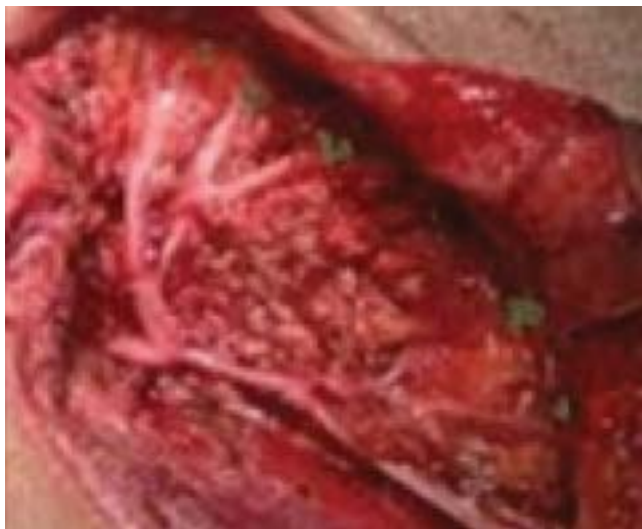

Figure 2: Branches of the Facial nerve.

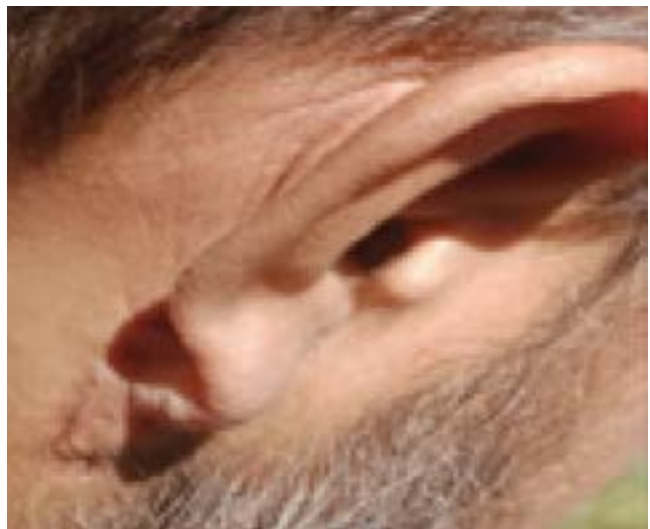

Figure 4: Post-operative follow-up.

released from surrounding parotid region, it was excised (Figure 3) and sent for histopathology. Layered closure was done. A drain was placed for 24 hrs. Facial nerve examination was done, the nerve was concluded to be functional post-operatively. Mild pain was relieved with analgesics. Patient was regularly followed up. (Figure 4)

DISUCSSION

DCs are benign lesions that can affect any part of the body with availability of skin nearby. These cysts contain cells of ectodermal and mesodermal origin which become entrapped in the deeper layers of tissues during embryonic, fetal or postnatal life^{1,2,3}.

In the parotid gland DCs are believed to develop as a result of either entrapment of cells during the closure of embryonic branchial arches, or due to impaction of ectodermal and dermal cells into the deeper tissue layers^{4,5}. When such cysts develop fully, they contain squamous cells with keratin and

dermal subunits such as hair follicles, sebaceous cells or sweat glands. Approximately 1-5% of all the lesions presenting in the parotid are cystic, however DCs are comparatively rare in this location, only a handful of cases have been published so far. To best of our knowledge, total 20 DC in the 18 prior case reports have been published in the literature till date⁵.

Most common complaint is a slowly growing, painless mass. On palpation it is usually fluctuant or non-fluctuant, mobile, non-tender mass^{1,2,5,6}.

To diagnose, several investigative tools can be utilized. Ultrasound is the most widely available, cheap, and non-invasive method and is mainly used to differentiate solid from cystic lesions and to evaluate the presence of blood vessels^{5,6,7}. Differential diagnosis includes pleomorphic adenoma, lipoma, mucous retention cyst, lymphoepithelial cyst, branchial cleft cyst, suppurative infection, fibroma or neurofibroma and obstructed parotid duct^{7,8,9}.

Both Computed Tomography (CT) and Magnetic Resonance Imaging (MRI) provide information regarding the morphology of the mass, along with its relation to the surrounding tissues. On CT-scan, the mass usually appears to be cystic, containing hypodense center inside the parenchyma of the parotid gland. On MRI, diagnosis of lipoma can be excluded due to the absence of fat in the mass. FNAB is another effective diagnostic method. All these diagnostic tools aid in the differential diagnosis of the cystic lesions preoperatively^{3,6,9}. In our case, FNAB was inconclusive. Definitive diagnosis should always be made by histopathological examination of the resected specimen^{2,3,10}.

Surgical removal of the mass by partial or total parotidectomy, with complete resection of the cyst, securing facial nerve branches, is recommended^{1,2,3,10}. Incomplete resection leads to recurrence. In our case the patient was treated with superficial parotidectomy with intact facial nerve¹⁰.

CONCLUSION

DCs are benign lesions that rarely occur in the parotid gland. Histopathology gives the clear diagnosis. During parotidectomy facial nerve should be protected where possible.

REFERENCES

1. Naujoks C, Handschel J, Braunstein S, et al. Dermoid cyst of the parotid gland—a case report and brief review of the literature. *Int J Oral Maxillofac Surg.* 2007;36(9):861–863.
2. Dwivedi G, Gupta V, Patnaik U, et al. Dermoid Cyst of the Parotid Gland: A Rare Entity. *Indian J Otolaryngol Head Neck Surg.* 2019;71(Suppl 1):809-812.
3. Gonzalez-Perez LM, Crespo-Torres S. Dermoid cyst of the parotid gland. *Oral Radiol.* 2013; 29:92–95.
4. Devine JC, Jones DC. Carcinomatous transformation of a sublingual dermoid cyst: a case report. *Int J Oral Maxillofac Surg.* 2000; 29(2):126–127.
5. Arslan F, Tasli H. Dermoid cyst of the parotid gland: Report of a rare entity with radiological findings and treatment approaches. *Egypt J Otolaryngol.* 2019; 35:367–369.
6. Yigit N, Karslioglu Y, Yildizoglu U, et al. Dermoid cyst of the parotid gland: report of a rare entity with literature review. *Head Neck Pathol.* 2015;9:286–292.
7. Kanaujia SK, Singh A, Nautiyal S, et al. Basal cell adenoma of parotid gland: case report and review of literature. *Indian J Otolaryngol Head Neck Surg.* 2015; 67:430–433.
8. Glaas MF, Schipper J, Kajasi N, et al. The youngest reported and successfully treated patient with a dermoid cyst of the parotid gland: a rare pediatric case. *Case Rep Otolaryngol.* 2017;2017: 1-4.
9. Sabhalok SS, Shetty LS, Sarve PH, et al. Epidermoid and dermoid cysts of the head and neck region. *Plast Aesthet Res.* 2016;3(suppl 1):347–350.
10. Shakeel M, Keh SM, Chapman A, et al. Intra-parotid dermoid cyst: Excision through a face lift incision. *J Coll Physicians Surg Pak.* 2014;24 (Suppl. 3): 238–239.
